

# TMJ Disc Displacement Angle Analysis in MRI: A New Proposal

## Correlation of MRI and Clinical Findings in Symptomatic Temporomandibular Joint Patients: A Cross Sectional Study

Aniket U. Vaidya\*, Nivedita Chinam, Manisha M. Khorate, Nigel Figueiredo

Department of Oral Medicine & Radiology, Goa Dental College & Hospital, Bambolim, Goa, India

*Received May 20, 2020; Revised July 4, 2020; Accepted July 20, 2020*

### *Cite This Paper in the following Citation Styles*

(a): [1] Aniket U. Vaidya, Nivedita Chinam, Manisha M. Khorate, Nigel Figueiredo, "TMJ Disc Displacement Angle Analysis in MRI: A New Proposal," *Open Journal of Dentistry and Oral Medicine*, Vol. 8, No. 2, pp. 11 - 16, 2020. DOI: 10.13189/ojdom.2020.080201.

(b): Aniket U. Vaidya, Nivedita Chinam, Manisha M. Khorate, Nigel Figueiredo (2020). *TMJ Disc Displacement Angle Analysis in MRI: A New Proposal*. *Open Journal of Dentistry and Oral Medicine*, 8(2), 11 - 16. DOI: 10.13189/ojdom.2020.080201.

Copyright©2020 by authors, all rights reserved. Authors agree that this article remains permanently open access under the terms of the Creative Commons Attribution License 4.0 International License

**Abstract Objective:** To evaluate the correlation of clinical symptoms and MRI findings of TMJ in symptomatic Temporomandibular Dysfunction (TMD) patients. **Material and Method:** MRI TMJ scan of 25 patients were evaluated. The subjects had clinical evidence of reciprocal TMJ clicking or restricted mouth opening. This study determined the variability of temporomandibular joint (TMJ) disk position in antero-posterior aspect of the joint using magnetic resonance imaging (MRI). Disk position was evaluated on MRI by measuring the angle formed by a line through the middle of the condyle and tangential to the posterior-most aspect of the disk. Joint effusion was checked using T2 weighted image sequence. Thickness of superior and inferior head of lateral pterygoid muscle was measured. These MRI findings were then correlated statistically to clinical findings. **Results:** Out of 50 TMJ's (25 patients); 40% had biconcave shape (no deformity), 16% cases showed lengthened disc, 12% cases showed a flattened disc, 12% cases showed thick posterior band. Varying degrees of disc displacement was associated with disc shape deformity. Increased thickness of Inferior head of lateral Pterygoid had statistically strong association with pain. **Conclusion:** A strong positive correlation was seen between the clinical and MRI findings in symptomatic TMD patients. Further using this, a new Disc Displacement

angle measurement method and classification of disc shape was proposed for better disc evaluation.

**Keywords** Temporomandibular Joint Disc, Magnetic Resonance Imaging, Temporomandibular Joint Dysfunction Syndrome

---

## 1. Introduction

One of the most common problems affecting Temporomandibular Joint (TMJ) is internal derangement. [1] This includes the abnormal relationship of the articular disc to the mandibular condyle, the fossa, and the articular eminence. Hence, these alterations have been also referred to as disc derangement. [2] Anterior Disc Displacement with reduction (ADDR) and Anterior Disc Displacement without reduction (ADDWOR) are the major findings in TMJ internal derangement whereas Posterior Disc Displacement is less common. MRI has been proven to be an excellent imaging technique for revealing the disc position in sagittal and coronal planes, shape of the disc, the condyle translation and to assess the thickness of the Lateral Pterygoid muscles. [2]

The aims of this study were to interpret MRI findings of

Temporomandibular Disorders (TMD's) and to find out correlation(s), if any, between the patient's signs and symptoms and MRI findings. The other objectives of this study were to propose a new method in assessment of degree of TMJ disc displacement in MRI.

## 2. Materials and Method

This cross-sectional pilot study involved evaluation of MRI scans of randomly selected 29 symptomatic TMD patients reporting to the department. Informed consent was obtained from the patients before the scan. Inclusion criteria were all symptomatic TMD patient above 18 years of age. Exclusion criteria were scans with motion artefacts, condyle fracture and TMJ ankylosis. Based on these 4 MRI scans were rejected due to motion artefacts. Hence MRI scans of 25 patients (50 TMJ's) were evaluated by two radiologists separately to avoid any bias. In cases where the opinion was found to differ, those were re-evaluated third time by both radiologists together to reach a consensus.

**MRI Protocol:** MRI scans were obtained on 1.5 Tesla Magnetom Avanto with brain coil using Syngo MRDR13 Software for interpretation. In the sagittal plane, proton density turbo spin-echo images were obtained in closed and open mouth positions. T2-weighted turbo spin-echo images were obtained in the open and close mouth position for all patients. All images were obtained with a section thickness of 3 mm. MRI analysis were carried out under following parameters; disc shape, types of disc displacement, disc displacement angle, thickness of superior and inferior head of Lateral Pterygoid muscle.

- Disc Shape:** It was evaluated in closed mouth position and disc shapes were categorized in to nine types as shown in Fig. 1
- Type of Disc Displacement:** It was evaluated in close and open mouth position. Based on 'disc reduction' or 'no disc reduction' from close to open mouth position, findings were recorded as anterior disc displacement with reduction (ADDR) and anterior disc displacement without reduction (ADDWOR) respectively.
- Disc Displacement Angle:** The Sagittal cut section in closed mouth position in which the disc was most prominently visible was selected and then the same image was imported to Adobe Acrobat Pro 9.0 software (Proximity Technology, 'A' Division of Franklin Electronic Publishers, Inc. Burlington, New Jersey, USA). Using the oval tool, a circle was marked over the condyle touching the inner margins of the superior, inferior and posterior surfaces, ensuring 'best fit'. Using the 'line tool' line 'A' was marked from the crest of articular eminence to the superior margin of external auditory meatus. Another line 'B' was marked which is tangent to the posterior surface of the articular disc. The disc displacement angle was measured between the long axis to the

condylar head and the line passing through the intersection of lines 'A' and 'B' (Fig. 2). The classification of disc displacement angle by Drace and Enzmann was followed (Table 1). [3]

- Lateral Pterygoid Muscle Thickness:** Measurements were carried out separately for the superior and the inferior head using the measurement tool provided with Syngo MRDR 13 software. (Fig. 3)

Each of the conditions evaluated were scored as present (1) or absent (0). Disc displacement angle was scored as 0,1,2,3 or 4.

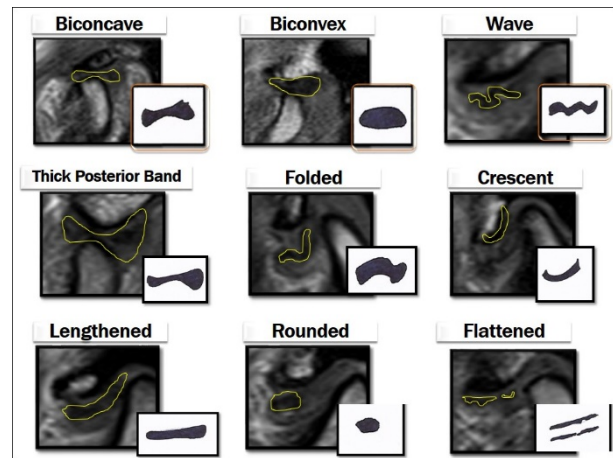


Figure 1. Nine Types of Disc Shapes Evaluated in this Study

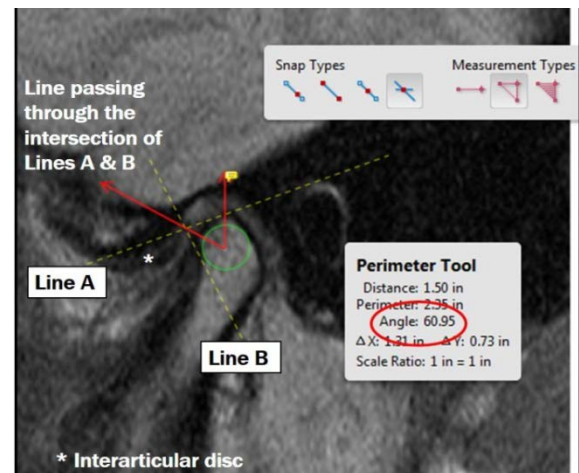
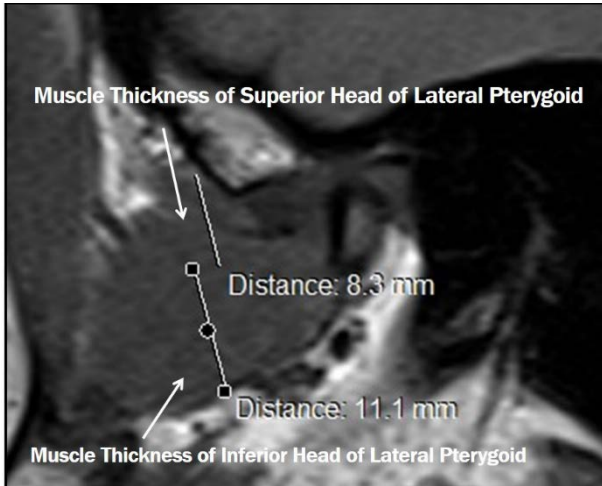


Figure 2. Measurement of Disc Displacement Angle:

Table 1. Classification of Anterior Disc Displacement (ADD) by Drace and Enzmann [3]

| Disc Displacement Grade | Displacement Angle   | Interpretation |
|-------------------------|----------------------|----------------|
| 0                       | 0 – 10 degrees       | Normal         |
| 1                       | 11 – 30 degrees      | Slight ADD     |
| 2                       | 31 – 50 degrees      | Mild ADD       |
| 3                       | 51 – 80 degrees      | Moderate ADD   |
| 4                       | More than 80 degrees | Severe ADD     |



**Figure 3.** Measurement of thickness of Superior and Inferior head of Lateral Pterygoid Muscle

### 3. Statistical Analysis

The data was tabulated using Microsoft Excel 2007 and analyzed using Statistical Package for Social Science (SPSS) software version 14.0 (SPSS Inc., Chicago, Illinois, USA). The Chi Square ( $\chi^2$ ) test was used to investigate the differences between the various MRI findings. Independent-samples t test was used to compare the thickness of Lateral Pterygoid muscle in patients with or without pain and in patients with DDR and DDWOR. Comparisons were considered significant at P value < 0.05.

### 4. Results

Total of 50 symptomatic TMJ's were evaluated in this study. The patients age ranged from 18 to 64 years (mean 31.7 years). The prevalence of TMD symptoms was found to be more in females compared to males with a ratio of 3.16:1 (**Table 2**)

**Type of Disc Displacement:** Association of pain was statistically significant with disc displacement without reduction. Association of joint sounds (clicking or crepitus) was statistically significant for both, disc displacement with and without reduction (**Table 3**).

**Table 2.** Basic Clinical Data of the Study Population

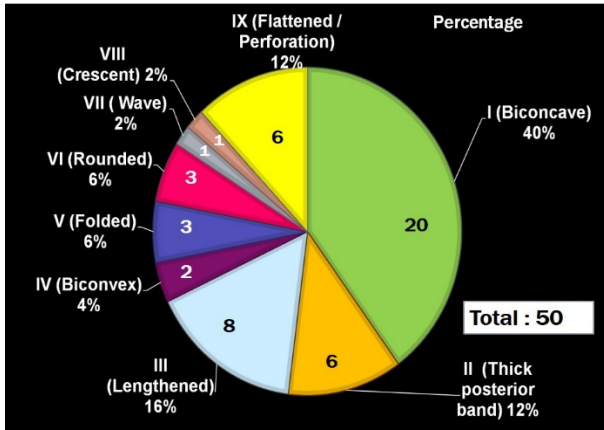
|  |                            |
|--|----------------------------|
| <b>Total No. of patients</b>               | <b>29</b>                  |
| No. of MRI scans excluded from study       | 4                          |
| No. of patients included in the study      | 25                         |
| No. TMJ evaluated                          | 50                         |
| Sex Distribution                           |                            |
| Males (%)                                  | 6 (24%)                    |
| Females (%)                                | 19 (76%)                   |
| Range of patient's age (mean age) in years | 18 – 64 years (31.7 years) |
| No. of patients with pain                  | 25                         |
| Males                                      | 6                          |
| Females                                    | 19                         |
| No. of patients with Joint sounds          | 15                         |
| Males                                      | 6                          |
| Females                                    | 9                          |

**Table 3.** Chi Square test to evaluate the association of pain and types of disc displacement and joint sounds

|       |              |         | NO | YES | Total | Chi Square | Df | P value |
|-------|--------------|---------|----|-----|-------|------------|----|---------|
| DDR   | Pain         | Absent  | 10 | 7   | 17    | 0.480      | 1  | 0.488   |
|       |              | Present | 16 | 17  | 33    |            |    |         |
|       | Total        | 26      | 24 | 50  |       |            |    |         |
| DDWOR | Pain         | Absent  | 17 | 0   | 17    | 9.050      | 1  | 0.003*  |
|       |              | Present | 20 | 13  | 33    |            |    |         |
|       | Total        | 37      | 13 | 50  |       |            |    |         |
| DDR   | Joint Sounds | Absent  | 24 | 1   | 25    | 38.78      | 1  | 0.000*  |
|       |              | Present | 2  | 23  | 25    |            |    |         |
|       | Total        | 26      | 24 | 50  |       |            |    |         |
| DDWOR | Joint Sounds | Absent  | 15 | 10  | 25    | 5.094      | 1  | 0.024*  |
|       |              | Present | 22 | 3   | 25    |            |    |         |
|       | Total        | 37      | 13 | 50  |       |            |    |         |

\*statistically significant

Df = Degree of Freedom



**Figure 4.** Pie Chart showing Frequency of Various Disc Shapes in the Study Sample

**Disc Shape:** Out of 50 TMJ’s 40% had biconcave shape (no deformity), 16% cases showed lengthened disc, 12% cases showed a flattened disc, 12% cases showed thick posterior band and remaining shapes were seen in lesser frequency. (**Fig. 4**)

**Disc Displacement Angle:**

Association of disc shape and disc displacement angle was checked by using Chi square test, the results are displayed in (**Table 4**). The discs with no shape deformity showed grade 0 disc displacement angle. Varying degrees of disc displacement was associated with disc shape deformity.

**Lateral Pterygoid Muscle Thickness:**

Independent T test was used to check alteration in the thickness of lateral Pterygoid muscle in patients having pain and disc displacement. Increased thickness of Inferior head of lateral Pterygoid had statistically strong association with pain (**Table 5**). Increased thickness of inferior head of lateral Pterygoid was also seen in all cases of disc displacement without reduction. Increase in the mean muscle thickness of superior head was seen in disc displacement without reduction as compared to disc displacement with reduction, although the results were not statistically significant (**Table 6**).

**Table 4.** Association of disc shape and disc displacement angle

| Disc Shapes              | Disc Displacement Angle |   |   |    |    | Total | Chi Square | (Df) | P value |
|--------------------------|-------------------------|---|---|----|----|-------|------------|------|---------|
|                          | 0                       | 1 | 2 | 3  | 4  |       |            |      |         |
| Biconcave (No Deformity) | 11                      | 5 | 0 | 4  | 0  | 20    | 47.62      | 32   | 0.037*  |
| Thick Posterior Band     | 1                       | 1 | 2 | 1  | 1  | 6     |            |      |         |
| Lengthened               | 0                       | 1 | 2 | 2  | 3  | 8     |            |      |         |
| Biconvex                 | 0                       | 0 | 1 | 0  | 1  | 2     |            |      |         |
| Folded                   | 0                       | 0 | 0 | 1  | 2  | 3     |            |      |         |
| Rounded                  | 0                       | 0 | 0 | 0  | 3  | 3     |            |      |         |
| Wave                     | 0                       | 0 | 0 | 1  | 0  | 1     |            |      |         |
| Crescent                 | 0                       | 0 | 0 | 0  | 1  | 1     |            |      |         |
| Flattened                | 0                       | 1 | 0 | 2  | 3  | 6     |            |      |         |
| <b>Total</b>             | 12                      | 8 | 5 | 11 | 14 | 50    |            |      |         |

\*statistically significant  
Df = Degree of Freedom

**Table 5.** Independent t test to evaluate thickness of Lateral Pterygoid muscle in patients with and without pain

| Lateral Pterygoid       | PAIN    | n  | Mean Thickness | SD     | SE Mean | P value |
|-------------------------|---------|----|----------------|--------|---------|---------|
| Thickness Superior Head | Absent  | 17 | 6.112          | 1.1401 | 0.2765  | 0.604   |
|                         | Present | 33 | 6.385          | 1.9884 | 0.3461  |         |
| Thickness Inferior Head | Absent  | 17 | 8.041          | 1.0338 | 0.2507  | 0.001*  |
|                         | Present | 33 | 9.712          | 1.8725 | 0.3260  |         |

\*statistically significant  
n = Sample  
SD = Standard Deviation  
SE = Standard Error

**Table 6.** Independent t test to evaluate thickness of Lateral Pterygoid muscle in patients disc displacement

| Superior Head |     | N  | Mean Muscle Thickness | SD    | P value |
|---------------|-----|----|-----------------------|-------|---------|
| DDR           | No  | 26 | 6.546 mm              | 1.852 | 0.868   |
|               | Yes | 24 | 6.017 mm              | 1.600 |         |
| DDWOR         | No  | 37 | 6.054 mm              | 1.459 | 0.054   |
|               | Yes | 13 | 6.969 mm              | 2.298 |         |
| Inferior Head |     |    |                       |       |         |
| DDR           | No  | 26 | 9.108 mm              | 1.905 | 0.317   |
|               | Yes | 24 | 9.183 mm              | 1.742 |         |
| DDWOR         | No  | 37 | 8.781 mm              | 1.631 | 0.015*  |

\*statistically significant

n = Sample

SD = Standard Deviation

## 5. Discussion

The magnetic resonance imaging helps in tissue differentiation based on measuring magnetic behavior and number of hydrogen proton in the human tissues when placed in the strong magnetic field. The advantages of MRI over conventional radiography include excellent soft tissue structure differentiation, imaging in various imaging planes and no harmful radiation. The MRI can demonstrate anatomical components of TMJ with great precision, good contrast resolution. However, there is a lack of the signal of the cortical bone (which appears black) on the all MRI sequences because there is low quantity of hydrogen protons in the cortical bone. [1]

In the present study, the prevalence of TMD symptoms in females is higher than males (Male - female prevalence ratio 1:3.16). Similarly, male-female prevalence ratios of 1:2.1 [2] and 1:4 [4] have been reported in the previous studies. It is well known that TMD is multifactorial and is attributed to numerous factors like discrepancy in occlusion, restorative procedures, orthodontic treatment, parafunctional habits, improper posture, emotional stress, trauma, etc. In the present study due to lack of standardization of examination procedures, no specific conclusions can be drawn so as to identify the factors causing higher prevalence of TMD in females. However, higher prevalence in females can explained by behavioral or psychological factors. In general, women have to tackle multiple tasks and endure many responsibilities on daily basis which can add to their mental stress level and causing a stressful lifestyle.

The results of our study showed that patients with previous history of pain and joint sounds (clicking or crepitus) had a higher rate of ADDWR. However, patients with presence of clinical joint sounds were also statistically associated with ADDR and pain may or may not be present in ADDR. This observation was similar to other studies in literature. [5, 6]

It has been seen that ADD is classified subjectively into categories based on complete or partial disc displacement with or without reduction. [2] This method is unreliable

and its reproducibility is questionable. In this study a more methodical approach for classification of ADD was adopted which is highly reproducible and can be used to study treatment outcomes and prognosis of patient at recalls. The methodology of disc displacement angle adopted by Incesu et al [7] is highly variable because in every patients' MRI imaging, the line passing through the summit of articular eminence and post glenoid tubercle does not pass through the centre of condylar head. This may be due to the fact that the position of the condyle and the disc is variable within the glenoid fossa [8] and considering disc displacement in medio-lateral aspect, the disc might not be visible in the same sagittal section which passes through the centre of the condyle. As opposed to this shortcoming, in our study, using the centre of the reference circle which is drawn to as "best fit" to the condyle width in the sagittal slice will ensure standardisation of the degree of ADD measurements. This allows the diagnostician to closely monitor the prognosis of the patient during and after the treatment. The possible drawback of this method can be that it is a time-consuming method.

With regard to disc configuration, Biconcave (40%), Thick posterior band (12%), Lengthened (16%), Biconvex (4%), Folded (6%), Round (6%), Wave (2%), Crescent (2%) and Flattened / Perforation (12%) was observed in our study. Taskaya-Yilmaz et al [9] reported frequencies of disc shape as Folded (18%), Lengthened (19.55%), Round (9.77%), Biconvex (7.51%) and Thick posterior band (3.75%). Incesu et al [7] reported that disc shapes like thick posterior band, rounded, lengthened and folded were associated with a posteriorly placed condyle within the glenoid fossa and they attributed it to degenerative changes and fibrotic alterations in posterior bilaminar zone. Although there is no significant data in the literature to support this finding. Murakami et al [10] listed 5 types and Taskaya-Yilmaz et al [9] reported 6 types of disc configuration in their studies. In addition to these, in the present study 3 additional disc shapes were identified namely, Crescent, Wave and Flattened / Perforated type. However, the authors like to point out one limitation of the present study that is small sample size. Since this study was

designed to be a pilot only 25 patients (50 TMJ's) were included. This will be followed by recruitment of larger sample size so as to determine the frequency of appearance of Crescent, Wave and Flattened / Perforated type of disc in a larger population.

Results of our study showed association of increased thickness of inferior attachment of LPM with pain and ADD similar findings were reported in other studies.[2, 11] Tomas et al [11] stated that inferior head of LPM may become hyperactive in internal derangement so as to stabilize and position the disc which leads to increased thickness of the muscle. Bony erosions of the condyle and joint effusion were less frequently seen in this series.

## 6. Conclusions

MRI findings like thickness of Inferior head of Lateral Pterygoid, Disc shape and Disc displacement angle can be successfully used to evaluate internal derangement. Disc displacement angle measurements can be carried out to closely monitor prognosis at follow ups. Therefore, MRI is warranted in every case so as provide optimum diagnostic benefits to the patients.

## Glossary of Abbreviations

ADDR: Anterior Disc Displacement with Reduction

ADDWOR: Anterior Disc Displacement Without Reduction

MRI: Magnetic Resonance Imaging

TMD: Temporomandibular Dysfunction

TMJ: Temporomandibular Joint

## Source of Funding or Financial Interest

This research did not receive any specific grant from funding agencies in the public, commercial, or not-for-profit sectors.

## Conflict of Interest

None

---

## REFERENCES

- [1] Marotti M. Imaging of Temporomandibular Joint Disorders. *Rad 507. Medical Sciences*, 2010; 34: 135-48.
- [2] Hasan NMA, Abdelrahman TEF. MRI evaluation of TMJ internal derangement: Degree of anterior disc displacement correlated with other TMJ tissue and osseous abnormalities. *The Egyptian Journal of radiology and Nuclear Medicine* 2014;45:735-44.
- [3] Drace JE, Enzmann DR. Defining the normal temporomandibular joint closed-, partially open-, and open-mouth MR imaging of asymptomatic subjects. *Radiol* 1990; 177: 67-71
- [4] Whyte AM, McNamara D, Rosenberg L. Magnetic Resonance Imaging in the evaluation of temporomandibular joint disc displacement- a review of 144 cases. *Int J Oral Maxillofac Surg* 2006;33:696-703.
- [5] Bertam S, Rudisch A, Innerhofer K, Pumpel E, Grubwieser G, Emshoff R. Diagnosing TMJ internal derangement and osteoarthritis with magnetic resonance imaging. *J Am Dent Assoc.* 2001;132:753-61
- [6] Emshoff R, Brandlmaier I, Gerhard S, Strobl H, Bertam S, Rudisch A. Magnetic resonance imaging predictors of temporomandibular joint pain. *J Am Dent Assoc* 2003;134:705-14.
- [7] Incesu L, Taskaya-Yilmaz N, Ogutcen-Toller M, Uzun E. Relationship of condylar position to disc position and morphology. *European Journal of Radiology* 2004;51:269-73.
- [8] Blaschke D, Chase DC. Differences in TMJ condyle temporal relationships in normal men and women. *J Dent Res* 1984;63:266-72.
- [9] Taskaya-Yilmaz N, Ogutcen Toller M. Magnetic Resonance Imaging Evaluation of Temporomandibular Joint Disc Deformities in Relation to Type of Disc Displacement. *J Oral Maxillofac Surg* 2001;59:860-65.
- [10] Murakami S, Takahashi A, Nishiyama H, Fujishita M, Fuchihata. Magnetic Resonance Evaluation of the Temporomandibular Joint Disc Position and Configuration. *Dentomaxillofac Radiol* 1993;22:205-7.
- [11] Tomas X, Pomes J, Berenguer J, Quinto L, Nicolau C, Mercader JM, et al. MR imaging of temporomandibular joint dysfunction: a pictorial review. *RadioGraphics* 2006;26:765-81.