

“Stitch in Time Saves Nine”-Cardiac Tamponade during Percutaneous Transvenous Mitral Commissurotomy(PTMC)-Stitching Phenomenon

Rajshekhhar I Koujalgi, Prem Krishna Anandan*, Harsha Basappa, Cholenahally Nanjappa Manjunath

Sri Jayadeva Institute of Cardiovascular Science & Research, India

Copyright © 2015 by authors, all rights reserved. Authors agree that this article remains permanently open access under the terms of the Creative Commons Attribution License 4.0 International License

Abstract An inadvertent puncture during PTMC in the region where right atrium (RA) and left atrium (LA) have overlapping walls may lead the catheter/needle to perforate the right atrial wall, enter the pericardial space and then enter the LA leading to “stitching phenomenon”. We describe a case of cardiac perforation resulting in cardiac tamponade during PTMC due to stitching phenomenon, promptly recognized and managed, completed PTMC and referred to surgery for cardiac perforation repair.

Keywords Cardiac Tamponade, Percutaneous Mitral Commissurotomy, Stitching Phenomenon

dilated left atrium (LA) and inter atrial septum (IAS) bulging towards right atrium (RA). There was a mean gradient of 22/16 mm Hg across mitral valve. TEE revealed absence of clot in Left Atrium (LA) and Left Atrial Appendage (LAA). Coronary angiography done through right femoral artery showed insignificant coronary artery disease.

Using standard fluoroscopic landmarks [2] during PTMC following transseptal puncture, entry of needle into LA was confirmed by recording LA pressure and contrast injection. A 14 F dilator was used to dilate the transseptal puncture site. On withdrawal of dilator, the BP dropped from 120/80 to 80/40 mmHg and subsequently the pulsations of left border of cardiac silhouette on fluoroscopy were diminished with possibility of cardiac tamponade due to cardiac perforation, confirmed subsequently by TTE. An echo guided pericardiocentesis was performed by introducing a 7F pigtail catheter through 7F sheath into the pericardial sac from subxiphoid approach. Pericardial aspiration was initiated along with inotropic support and autologous transfusion of the pericardial aspirate thereby stabilizing the patient hemodynamically. Subsequently on attempted withdrawal of 14F dilator from LA to RA there was rapid collection of blood in pericardial sac along with fall of BP, prompting to readvance the 14F dilator in an attempt to reocclude the false track. Following this the pericardial collection reduced, confirmed by echocardiography and the patient remained hemodynamically stable.

Further after hemodynamically stabilizing the patient a successful PTMC was done through a fresh transseptal puncture and mitral valve was dilated with accurate balloon resulting in mitral valve orifice area of 1.7 cm² by planimetry and gradient across mitral valve reduced to 12/7 mm Hg with trivial mitral regurgitation. This procedure reduced the LA pressure leading to further decreased pericardial collection, stabilizing (heart rate 96/min and blood pressure 110/70 mm Hg) the worsening hemodynamics.

Since the earlier 14F dilator parked at the presumed transseptal puncture site had temporarily sealed the cardiac perforation leading to temporary stabilization of

1. Introduction

Cardiac tamponade secondary to cardiac perforation following percutaneous transvenous mitral commissurotomy (PTMC) with an incidence of 0 to 9% in several studies[1], account for half of procedure related mortalities, and is often managed by surgery if hemodynamically unstable. Though with the advent of Inoue balloon, perforations in left ventricle (LV) have decreased during transseptal puncture for PTMC, sometimes perforations at other sites occur, during or after transseptal puncture even under guidance of trans esophageal echocardiography (TEE).

2. Case Report

A 50-year-old lady presented with breathlessness of NYHA class III, in sinus rhythm, chest x-ray showing features of pulmonary venous hypertension with dilated pulmonary artery and left atrial enlargement. On two dimension transthoracic Echocardiography (TTE) and Doppler evaluation she was found to have severe mitral stenosis with mitral valve orifice area of 0.9 cm² by planimetry and Wilkin’s score of (8/16) associated with

hemodynamics, a surgical repair of cardiac perforation was planned. As Activated clotting time was 158 seconds with additional heparin the thrombogenic Accura balloon was withdrawn with the coiled wire still in LA and a 14 F dilator placed in the LA largely sealing the false tract at the site of the presumed IAS puncture site (Fig. 1a). And pericardial sheath with pigtail catheter in situ, patient was transferred to surgical facility after intimation to surgical team. The cardiac perforation was surgically repaired successfully and patient remained asymptomatic on follow up after a month.

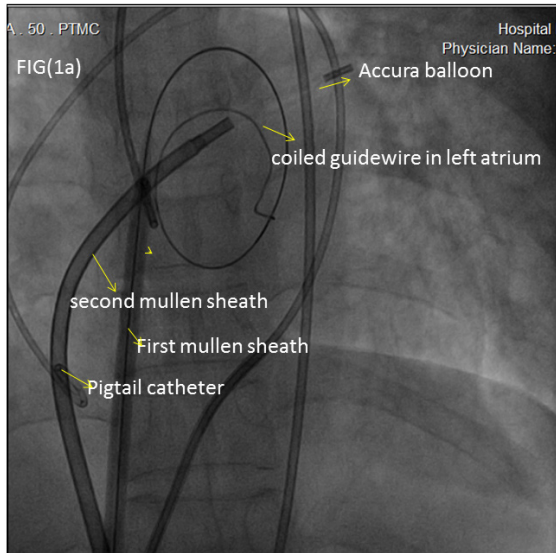


Figure 1a. From right to left showing first mullen sheath & pigtail catheter in-situ and second transseptal puncture with second mullen sheath and accura balloon to complete percutaneous trans luminal mitral commissurotomy.

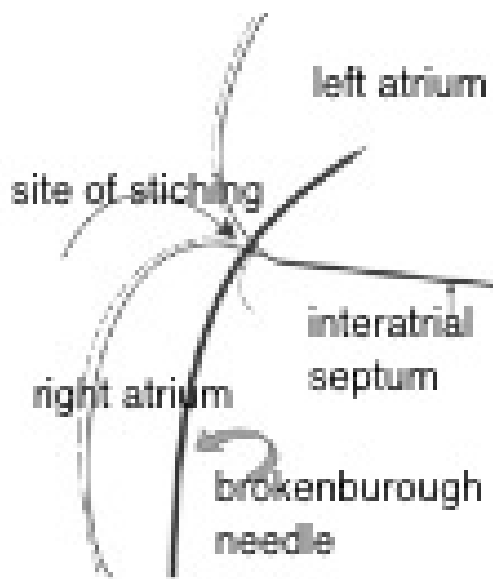


Figure 1b. Schematic representation of stitching phenomenon

3. Discussion

The mid septum being an ideal site of transseptal puncture during PTMC is often missed owing to distortion of anatomy in patients with mitral stenosis and under fluoroscopic

guidance leads to inadvertent puncture of the aorta, coronary sinus or high lateral/inferior atrial wall (without penetrating the septum)[3] where there is no atrial septum in this region and beyond.

“Stitching phenomenon”

Especially in patients with large LA there is no atrial septum in the region beyond or near the right lateral or inferior borders of the LA shadow when viewed in frontal projection. An inadvertent puncture in this region where RA and LA have overlapping walls may lead the catheter/needle to perforate the right atrial wall, enter the pericardial space and then enter the LA(Fig 1b) leading to “stitching phenomenon”.

The perforation in our case lead to bleeding in the pericardial space and pericardial tamponade, mostly from the high pressure LA and also from RA after guidewire was placed in the LA and path dilated. This cannot be detected by pressure recording, oximetry or contrast injections .The 14F dilator which was kept across the false track sealing it temporarily and the initiation of pericardiocentesis along with inotropes and autologous transfusion stabilized the patient hemodynamically. The preferred option is to surgically seal the perforation and do surgical mitral commissurotomy. Since the surgical center was not proximate and with the experience of a large number of PTMC procedures in our center, we have evolved a strategy of taking care of the bleeding from high pressure LA side into pericardial space by performing PTMC quickly through a new transseptal puncture along with simultaneous pericardiocentesis. This allows Post- PTMC, the LA pressure to decrease along with the 14F dilator in situ occluding the false track, thereby decreasing filling of pericardial space. Further intravenous fluids can be freely used in resuscitation of tamponade after opening of mitral valve. However a calculated risk was taken to avoid risk of significant mitral regurgitation and subsequent worsening hemodynamics by under dilating the mitral valve. An unstretched Accura balloon parked across the presumed puncture site may stabilize hemodynamics and at this point most of our patients are referred to surgery. However, since the surgical team was preoccupied and at a nearby surgical facility, in present case, we decided to exchange the balloon with the 14 F dilator, as it is less thrombogenic and thus reducing the risk of clot formation and embolization. Sometimes gradually withdrawing the dilator over the next few minutes followed by the coiled wire may obviate the need for surgery. Reports of glue injection to seal the perforation have also been described [4]. Since coiled wire and 14F dilator kept for longer time may increase risk of clot formation in LA and embolization, in the absence of any anticoagulation we aimed to promote clotting in the false tract and the pericardium thereby reducing pericardial collection. Further the clot may undergo autolysis after some time leading to late re-bleed. In our case, any attempt to withdraw the 14 F dilator led to immediate and significant worsening of hemodynamics, thus avoiding this method. At

this point surgery was inevitable and hence patient was transferred to a surgical facility and successfully underwent repair of cardiac perforation.

4. Conclusions

The key to a safe and successful PTMC is a well-executed transseptal catheterisation, awareness of distorted anatomy of inter atrial septum in mitral stenosis and prompt recognition and management of cardiac tamponade. PTMC can still be completed with a second septal puncture after stabilizing the patient hemodynamically.

REFERENCES

- [1] Joseph G, Chandy ST, Krishnaswami S, Ravikumar E, Korula RJ. Mechanisms of cardiac perforation leading to tamponade in balloon mitral valvuloplasty. *Catheter Cardiovasc Diagn* 1997; 42: 138–146
- [2] Inoue K, Hung JS, Chen CR, et al. Mitral stenosis: Inoue balloon catheter technique. In: Cheng TO (ed). *Percutaneous Balloon Valvuloplasty*. New York: Igaku-Shoin, 1992, pp 237–279
- [3] Hung JS. Atrial septal puncture technique in percutaneous transvenous mitral commissurotomy: mitral valvuloplasty using the Inoue balloon catheter technique. *Catheter Cardiovasc Diagn* 1992;26: 275–284.
- [4] Trehan et al. Novel non-surgical method of managing cardiac perforation during percutaneous transvenous mitral commissurotomy. *Indian Heart Journal* 56(4):328-32.